Jurnal Ilmiah Universitas Batanghari Jambi e-ISSN: 2549-4236, p-ISSN: 1411-8939
Lembaga Penellitian dan Pengabdian kepada Masyarakat
Vol 25, No 2 (2025): Juli, 1087-1092
DOI: 10.33087/jiubj.v25i2.5990

Complete Laparoscopic Excision and Bilio-digestive Reconstruction of a Type IA Choledochal Cyst

Michael Tendean[1], Marven Ayawaila[1], Toar D B Mambu[2], Ferdinand Tjandra[1], Billy E. Ch.R. Salem[1], Jimmy Panelewen[1], *Fanni Luciana[2]
[1]Staff of Digestive Surgery Division, General Surgery Department, Medical Faculty of Sam Ratulangi University, Prof. Dr. R. D. Kandou, Manado, Indonesia
[2]General Surgeon, Medical Faculty of Sam Ratulangi University, Prof Dr. R.D Kandou, Manado, Indonesia
*Correspondence: fanni.luciana.fl@gmail.com

Abstrak. Choledochal cysts (CC) adalah dilatasi langka dari struktur empedu yang dapat muncul sebagai anomali tunggal atau ganda, mempengaruhi saluran empedu intrahepatik atau ekstrahepatik. Kista bawaan ini diklasifikasikan ke dalam berbagai jenis berdasarkan lokasinya, termasuk tipe I, II, III, dan IVa, dengan tipe V mempengaruhi segmen intrahepatik. Secara tradisional, eksisi terbuka telah menjadi pengobatan standar; namun, eksisi laparoskopi telah diterima secara global sejak diperkenalkan. Penelitian menggambarkan kasus yang melibatkan seorang wanita berusia 42 tahun yang mengalami nyeri kuadran perut kanan atas dan penyakit kuning intermiten, dengan MRI sebelumnya mengungkapkan kista koledokal tipe 1A yang mempengaruhi pertemuan saluran hati ke saluran empedu umum. Pasien menjalani eksisi laparoskopi lengkap dari kista koledokal, diikuti oleh hepaticojejunostomi Roux-en-Y untuk rekonstruksi bilio-pencernaan. Meskipun kebocoran empedu pasca operasi diamati di saluran pembuangan, itu sembuh pada hari pasca operasi (POD) 5, dan pasien dipulangkan dengan POD 7 tanpa efek samping. Temuan menunjukkan bahwa operasi laparoskopi untuk Choledochal cysts adalah pilihan yang aman dan efektif, terkait dengan rawat inap yang lebih singkat, komplikasi pasca operasi yang lebih sedikit, dan penurunan kehilangan darah dibandingkan dengan operasi terbuka. Dengan kemajuan berkelanjutan dalam keterampilan dan teknik laparoskopi, eksisi laparoskopi akan menjadi metode yang lebih disukai untuk mengobati kista koleskopi.

Kata kunci: Kista Koledochal, Klasifikasi Todani, Hepaticojejunostomy

Abstract. Choledochal cysts (CC) are rare dilatations of the biliary tree that can present as single or multiple anomalies, affecting the intrahepatic or extrahepatic bile ducts. These congenital cysts are classified into different types based on their location, including types I, II, III, and IVa, with type V affecting the intrahepatic segment. Traditionally, open excision has been the standard of care; however, laparoscopic excision has gained global acceptance since its introduction. This study describes a case involving a 42-year-old woman who presented with right upper quadrant pain and intermittent jaundice, with previous MRI revealing a type 1A choledochal cyst affecting the confluence of the hepatic duct into the common bile duct. The patient underwent complete laparoscopic excision of the choledochal cyst, followed by Roux-en-Y hepaticojejunostomy for biliary-digestive reconstruction. Although postoperative bile leakage was observed in the duct, it resolved by postoperative day (POD) 5, and the patient was discharged on POD 7 without any adverse events. The findings suggest that laparoscopic surgery for choledochal cysts is a safe and effective option, associated with shorter hospital stays, fewer postoperative complications, and decreased blood loss compared with open surgery. With continued advancement in laparoscopic skills and techniques, laparoscopic excision will become the preferred method for treating choledochal cysts.

Keywords: Choledochal Cysts, Todani Classification, Hepaticojejunostomy

INTRODUCTION

The management of choledochal cysts, particularly Type IA, has evolved significantly with advancements in surgical techniques, especially laparoscopic approaches. Choledochal cysts are congenital anomalies characterized by cystic dilatation of the biliary tree, which can lead to serious complications such as cholangitis, pancreatitis, and even malignancy if left untreated (Sun et al., 2020; K. Zhang et al., 2022). The standard treatment involves complete excision of the cyst and reconstruction of the biliary tract, typically through a Roux-en-Y hepaticojejunostomy (Cheng et al., 2024; Hakimi et al., 2022). This surgical intervention aims to restore normal biliary drainage while minimizing the risk of postoperative complications. Laparoscopic excision of choledochal cysts has gained traction due to its minimally invasive nature, which offers several

advantages over traditional open surgery, including reduced postoperative pain, shorter recovery times, and improved cosmetic outcomes (Bian et al., 2023; Qu et al., 2019). The laparoscopic approach, however, presents unique challenges, particularly in pediatric patients, where anatomical considerations and the size of the cyst can complicate the procedure (Lin et al., 2024; B. Zhang et al., 2019). Despite these challenges, studies have shown that laparoscopic techniques can be safely and effectively employed for the excision of choledochal cysts, with outcomes comparable to open surgery (Lee et al., 2021; K. Zhang et al., 2022). Recent meta-analyses have highlighted the efficacy and safety of laparoscopic excision in children, demonstrating favorable outcomes in terms of complication rates and recovery times (Sun et al., 2020; K. Zhang et al., 2022). The procedure typically involves careful dissection of the cyst from surrounding structures, ligation of the cystic duct, and subsequent reconstruction of the biliary tract. The Roux-en-Y technique is preferred due to its ability to create a stable anastomosis while minimizing the risk of bile leakage (Cheng et al., 2024; Hakimi et al., 2022). Furthermore, advancements in robotic-assisted surgery have introduced new possibilities for enhancing precision and control during these complex procedures (Chen et al., 2022; Jin et al., 2023).

Choledochal cysts (CCs) are rare congenital dilatations of the biliary tree that can affect the extrahepatic or intrahepatic segments, or both, and may occur in single or multiple locations (Le et al., 2006). While most cases are diagnosed during childhood, 20-25% are identified in adulthood, with an incidence of approximately 1 in 100,000 to 150,000 live births and a higher prevalence in females (Lu et al., 2015). Postoperative complications can be significant and may manifest even decades after surgery (Ray et al., 2023). CCs were first systematically classified by Alonso-LEJ et al. in 1959 into three types based on anatomical features, with subsequent expansions by Todani et al. in 1977, 1997, and 2003 (Meng et al., 2022). Type I CCs are further subdivided by morphology and location, with type IA involving the entire extrahepatic biliary system. Type II represents a saccular diverticulum of the common bile duct, type III (choledochocele) is an intramural dilation of the distal bile duct, type IV includes intra- and extrahepatic dilations (IVA and IVB), and type V (Caroli's disease) features dilations confined to intrahepatic bile ducts, often associated with congenital hepatic fibrosis termed Caroli's syndrome (Bhavsar et al., 2012; Xiao et al., 2022). Types IA, IC, and IVA are frequently associated with pancreaticobiliary maljunction, and types I and IV carry high risks of complications such as intrahepatic stones, cholangitis, strictures, and malignancies (Xiao et al., 2022). Treatment typically involves cholecystectomy and cyst resection with biliary-enteric reconstruction, most commonly using the Roux-en-Y method, though hepatic-duodenal anastomosis is an effective alternative (Han et al., 2021; Mukai et al., 2018; Ray et al., 2023).

In conclusion, the laparoscopic excision and bilio-digestive reconstruction of Type IA choledochal cysts represent a significant advancement in the surgical management of this condition. The combination of minimally invasive techniques and careful surgical planning has led to improved patient outcomes, making this approach a preferred option in contemporary pediatric surgery. As the field continues to evolve, ongoing research and clinical experience will further refine these techniques, ensuring optimal care for patients with choledochal cysts.

CASE

A 42-year-old woman presented with upper right abdominal quadrant pain and intermittent jaundice, with no significant drug or family history or relevant psychosocial background. Physical examination revealed tenderness in the right upper quadrant, a palpable mass, and hepatomegaly extending below the costal margin. Laboratory findings showed elevated transaminases, pancreatic enzymes, and signs of cholestasis. An initial ultrasound was inconclusive, but prior MRI identified a type 1A choledochal cyst involving the hepatic duct confluence to the common bile duct. Preoperative preparations included antibiotic prophylaxis, and under general anesthesia, a transumbilical incision was made with port placement for laparoscopic access (**Figure 1**).

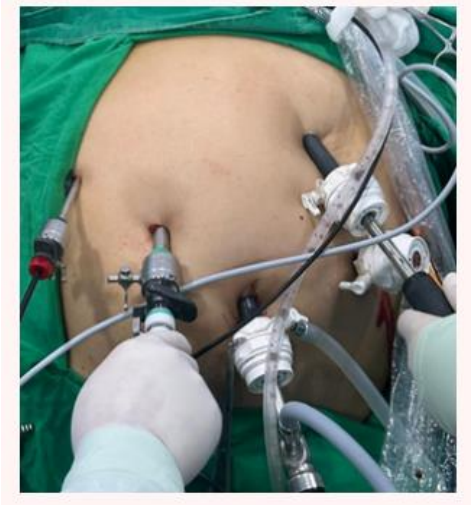

Figure 1. Laparoscopic Ports Insertion

Careful dissection revealed firm adhesions in the bile duct and liver, exposing a fusiform cyst measuring approximately 7x7 cm, which was removed via the umbilical port after identifying and clipping the left hepatic duct (**Figure 2**). Subsequent jejuno-jejunal anastomosis was performed 60 cm from the Treitz angle, followed by Roux-en-Y hepaticojejunostomy using 3-0 Vicryl sutures. Hemostasis and cavity washout were ensured, and a Jackson drain was placed. The procedure lasted 7 hours with 300 cc blood loss. Postoperative bile leakage was observed but resolved by postoperative day 5, and the patient was discharged on day 7 without any complications.

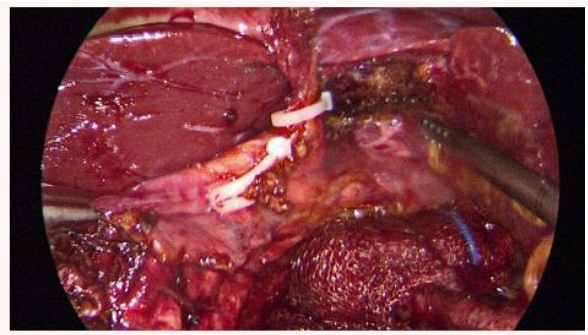

Figure 2. Dissection, Clipping and Removal of The Cyst

RESULT

Choledochal cysts are rare congenital anomalies of the biliary system characterized by abnormal dilatations of the bile ducts, which can involve the extrahepatic, intrahepatic, or both regions of the biliary tree. Although these conditions are uncommon, they are well-documented in medical literature due to their significant clinical implications. The incidence is approximately 1 in 100,000 to 150,000 live births, with a predominance in females, and while most cases are diagnosed during childhood, a significant proportion approximately 20-25% are identified in adults. These late-diagnosed cases often present with more complex clinical manifestations and a higher likelihood of complications, such as biliary stones, strictures, cholangitis, and, notably, cholangiocarcinoma.

The accurate diagnosis of choledochal cysts is critical for appropriate management and long-term outcomes. Ultrasound is one of the most valuable diagnostic tools in detecting type I choledochal cysts, which represent the most common form of this condition. Type I cysts involve a fusiform dilation of the extrahepatic bile ducts and are subdivided into subtypes based on morphology and anatomical location. Despite its utility, the accuracy and efficacy of ultrasound in identifying choledochal cysts are heavily reliant on the experience and expertise of the radiologist interpreting the images. Misinterpretation can lead to delayed diagnosis or mismanagement, which is particularly concerning given the associated risks.

Among the most significant risks in patients with choledochal cysts is the development of cholangiocarcinoma. This bile duct cancer is associated with chronic inflammation and biliary stasis, both of which are common in patients with choledochal cysts. Studies suggest that the risk of cholangiocarcinoma in individuals with choledochal cysts can be as high as 10-30%, highlighting the importance of timely diagnosis and definitive treatment. Radical surgical resection of the cysts is considered the gold standard of care, aimed at eliminating the potential nidus for malignancy and alleviating the associated biliary complications. In most cases, radical resection is accompanied by a biliary-enteric reconstruction, commonly performed as a Roux-en-Y hepaticojejunostomy.

The Roux-en-Y anastomosis is a surgical procedure that creates a connection between the hepatic duct and the jejunum, bypassing the duodenum and distal bile duct. This method is widely accepted due to its efficacy in preventing bile reflux, which can contribute to further complications such as ascending cholangitis. The procedure is complex and traditionally performed via open surgery; however, advancements in surgical techniques

have led to the adoption of minimally invasive approaches. Laparoscopic surgery, in particular, has gained attention for its potential to reduce recovery time, minimize postoperative pain, and decrease the risk of surgical-site infections.

Laparoscopic techniques for choledochal cyst management were first introduced in 1995, marking a significant milestone in the surgical treatment of this condition (Shen et al., 2015; Zhen et al., 2015). Since then, laparoscopic resection of choledochal cysts has been increasingly performed in pediatric populations, where the benefits of minimally invasive surgery are particularly pronounced. However, reports of laparoscopic management in adult cases remain limited in the literature, possibly due to the complexities associated with the condition in older patients. Adult patients often present with larger cysts, more extensive adhesions, and a higher incidence of comorbidities, all of which can complicate laparoscopic procedures. Despite these challenges, the continued refinement of laparoscopic techniques has enabled surgeons to achieve comparable outcomes to open surgery in terms of safety and efficacy.

In the present case, we performed a laparoscopic resection and Roux-en-Y anastomosis for a 42-year-old woman diagnosed with a type I choledochal cyst. The patient presented with upper right abdominal quadrant pain and intermittent jaundice, which are common clinical manifestations of choledochal cysts in adults. Physical examination revealed tenderness and a palpable mass in the right upper quadrant, accompanied by hepatomegaly. Laboratory findings showed elevated transaminases and pancreatic enzymes, alongside markers of cholestasis, further supporting the suspicion of a biliary obstruction. Initial ultrasound imaging was inconclusive, emphasizing the limitations of this modality in certain cases. However, an MRI provided definitive evidence of a type IA choledochal cyst involving the hepatic duct confluence to the common bile duct.

Surgical management of the patient involved a minimally invasive approach using laparoscopic techniques. Under general anesthesia, a transumbilical incision was made to allow the placement of laparoscopic ports. Careful dissection was undertaken to address firm adhesions between the bile duct and surrounding structures, which are commonly encountered in adult patients with long-standing choledochal cysts. A fusiform cyst measuring approximately 7x7 cm was identified, dissected, and removed via the umbilical port. The Roux-en-Y hepaticojejunostomy was then constructed using 3-0 Vicryl sutures, ensuring a secure and leak-free anastomosis. Additionally, a jejuno-jejunal anastomosis was performed 60 cm distal to the Treitz ligament to facilitate biliary drainage. Thorough hemostasis and cavity washout were achieved before placing a Jackson drain to monitor for potential postoperative complications.

The surgical procedure lasted approximately seven hours, with an estimated blood loss of 300 cc. Postoperative bile leakage was observed through the Jackson drain, a complication that, while concerning, was managed conservatively. The bile leakage resolved by postoperative day 5 without necessitating additional interventions, and the patient was discharged on postoperative day 7 in stable condition. During follow-up, which ranged from 3 to 48 months, no complications or recurrences were noted, underscoring the efficacy and safety of the laparoscopic approach in managing adult choledochal cysts.

The successful outcome in this case highlights the advantages of laparoscopic surgery in the treatment of choledochal cysts, particularly in adult patients. The minimally invasive approach not only achieved the desired surgical objectives but also minimized patient morbidity and facilitated a swift recovery. Despite the challenges posed by the size and complexity of the cyst in this adult patient, meticulous surgical planning and execution were key to the favorable outcome. The lack of long-term complications further emphasizes the durability of the laparoscopic Roux-en-Y hepaticojejunostomy as a definitive treatment for choledochal cysts.

While this case adds to the growing body of evidence supporting laparoscopic management of choledochal cysts, it also underscores the need for further research. Adult cases, in particular, remain underrepresented in the literature, and larger studies are needed to establish standardized protocols and assess the long-term outcomes of minimally invasive techniques. The integration of advanced imaging modalities, such as MRI and MRCP, into the diagnostic workflow has already proven invaluable in preoperative planning, and ongoing advancements in laparoscopic equipment and techniques are likely to further

enhance the feasibility of this approach in complex cases.

CONCLUSION

Laparoscopic surgery for choledochal cysts has emerged as a safe and effective treatment option, offering several advantages over traditional open surgery. This minimally invasive approach is associated with shorter hospital stays, reduced postoperative complications, and significantly lower blood loss. These benefits make laparoscopic techniques particularly appealing for both patients and healthcare providers. Additionally, the minimally invasive nature of this method results in reduced postoperative pain and faster recovery, enhancing overall patient outcomes. A notable advantage of laparoscopic surgery is its cosmetic benefit, as the reuse of the trocar site for incision minimizes visible scarring. This is especially significant in younger patients or those concerned about postoperative appearance. The use of high-definition imaging during laparoscopic procedures also provides surgeons with enhanced visualization of the biliary anatomy, allowing for precise dissection and reconstruction, which is critical in the management of choledochal cysts. With ongoing advancements in laparoscopic skills and technology, this technique has become increasingly feasible for complex biliary surgeries, including those involving adult patients. While initially limited to pediatric cases, laparoscopic management of choledochal cysts in adults has shown comparable safety and efficacy, with favorable long-term outcomes. As surgical expertise continues to evolve and access to advanced equipment expands, laparoscopic surgery is poised to become the preferred method for the treatment of choledochal cysts, offering patients a less invasive alternative with excellent clinical results and aesthetic outcomes.

REFERENCES

Bhavsar, M., Vora, H., & Giriyappa, V. 2012. Choledochal Cysts : A Review of Literature. *Saudi Journal of Gastroenterology*, *18*(4), 230.

Bian, Z., Zhi, Y., Zeng, X., & Wang, X. 2023. Curative Effect and Technical Key Points of Laparoscopic Surgery For Choledochal Cysts in Children. *Frontiers in Surgery*, *9*, 1–7.

Chen, S., Lin, Y., Xu, D., Lin, J., Zeng, Y., & Li, L. 2022. Da Vinci Robotic-Assisted Treatment of Pediatric Choledochal Cyst. *Frontiers in Pediatrics*, *10*, 1–7.

Cheng, J., Yu, Q., Fu, J., & Li, P. 2024. Non-Stapled, Total Laparoscopic Roux-En-Y Anastomosis: A Safe and Effective Procedure for Radical Pediatric Choledochal Cyst Excision. *Surgery Open Science*, *17*, 49–53.

Hakimi, T., Esmat, H. A., & Karimi, R. 2022. Choledochal Cyst: A Challenging Diagnostic and Therapeutic Entity in Low-Resource Settings. *International Journal of Surgery Case Reports*, *90*, 106729.

Han, W. S., Kim, H., Sohn, H. J., Lee, M., Kang, Y. H., Kim, H. S., Han, Y., Kang, J.-S., Kwon, W., & Jang, J.-Y. 2021. Clinical Characteristics of Patients with Malignancy and Long-Term Outcomes of Surgical Treatment of Patients with Choledochal Cyst. *Annals of Surgical Treatment and Research*, *101*(6), 332.

Jin, Y., Zhang, S., Cai, D., Zhang, Y., Luo, W., Chen, K., Chen, Q., & Gao, Z. 2023. Robot-Assisted Resection of Choledochal Cyst in Children. *Frontiers in Pediatrics*, *11*, 1–6.

Le, L., Pham, A.-V., & Dessanti, A. 2006. Congenital Dilatation of Extrahepatic Bile Ducts in Children. Experience in the Central Hospital of Hue, Vietnam. *European Journal of Pediatric Surgery*, *16*(1), 24–27.

Lee, C., Byun, J., Ko, D., Yang, H.-B., Youn, J. K., & Kim, H.-Y. 2021. Comparison of Long-Term Biliary Complications Between Open and Laparoscopic Choledochal Cyst Excision in Children. *Annals of Surgical Treatment and Research*, *100*(3), 186–192.

Lin, Y., Chen, S., Lin, Y., Zhang, L., Wang, J., Qiu, X., Xu, D., & Li, L. 2024. A Trans-Umbilical Single-Site Plus One Robotic-Assisted Surgery For Choledochal Cyst Resection in Children. *Frontiers in Pediatrics*, *12*, 1–7.

Lu, B., Shen, Z., Yu, J., Yang, J., Tang, H., & Ma, H. 2015. Laparoscopic Surgery For Removal of Choledochal Cysts and Roux-En-Y Anastomosis. *International Journal of Clinical and Experimental Medicine*, *8*(8), 13013–13016.

Meng, Y., Guo, K., Jiang, Y., & Wei, S. 2022. Todani Type III: Like Biliary Dilatation with Duodenal Prolapse - A Case

Report. *BMC Gastroenterology*, *22*(1), 4–9.

Mukai, M., Kaji, T., Masuya, R., Yamada, K., Sugita, K., Moriguchi, T., Onishi, S., Yamada, W., Kawano, T., Machigashira, S., Nakame, K., Takamatsu, H., & Ieiri, S. 2018. Long-Term Outcomes of Surgery For Choledochal Cysts: A Single-Institution Study Focusing On Follow-Up and Late Complications. *Surgery Today*, *48*(9), 835–840.

Qu, X., Cui, L., & Xu, J. 2019. Laparoscopic Surgery in The Treatment of Children with Choledochal Cyst. *Pakistan Journal of Medical Sciences*, *35*(3), 807–811.

Ray, S., Dhali, A., Khamrui, S., Mandal, T. S., Das, S., & Dhali, G. K. 2023. Surgical Outcomes After Re-Operation For Excision of Choledochal Cyst with Delayed Biliary Complications: A Retrospective Study On 40 Patients. *The American Journal of Surgery*, *226*(1), 93–98.

Shen, H.-J., Xu, M., Zhu, H.-Y., Yang, C., Li, F., Li, K., Shi, W.-J., & Ji, F. 2015. Laparoscopic Versus Open Surgery in Children With Choledochal Cysts: A Meta-Analysis. *Pediatric Surgery International*, *31*(6), 529–534.

Sun, R., Zhao, N., Zhao, K., Su, Z., Zhang, Y., Diao, M., & Li, L. 2020. Comparison of Efficacy And Safety of Laparoscopic Excision and Open Operation in Children with Choledochal Cysts: A Systematic Review and Update Meta-Analysis. *PLOS ONE*, *15*(9), e0239857.

Xiao, J., Chen, M., Hong, T., Qu, Q., Li, B., Liu, W., & He, X. 2022. Surgical Management and Prognosis of Congenital Choledochal Cysts in Adults: A Single Asian Center Cohort of 69 Cases. *Journal of Oncology*, *2022*, 1–10.

Zhang, B., Wu, D., Fang, Y., Bai, J., Huang, W., Liu, M., Chen, J., & Li, L. 2019. Early Complications After Laparoscopic Resection of Choledochal Cyst. *Pediatric Surgery International*, *35*(8), 845–852.

Zhang, K., Zhao, D., Xie, X., Wang, W., & Xiang, B. 2022. Laparoscopic Surgery Versus Robot-Assisted Surgery For Choledochal Cyst Excision: A Systematic Review and Meta-Analysis. *Frontiers in Pediatrics*, *10*, 1–11.

Zhen, C., Xia, Z., Long, L., Lishuang, M., Pu, Y., Wenjuan, Z., & Xiaofan, L. 2015. Laparoscopic Excision Versus Open Excision for the Treatment of Choledochal Cysts: A Systematic Review and Meta-Analysis. *International Surgery*, *100*(1), 115–122.